

Note for John Doe on 8/1/2007 - Chart 13155

Consultation was requested by Dr. Full General, MD.

Chief Complaint (1/1): This 48 year old male presents today for a complete eye examination.

Allergies: Patient admits allergies to aspirin resulting in GI upset.

Medications: None.

PMH: Past medical history is unremarkable.

Past Surgical History: Patient admits past surgical history of appendectomy in 1989.

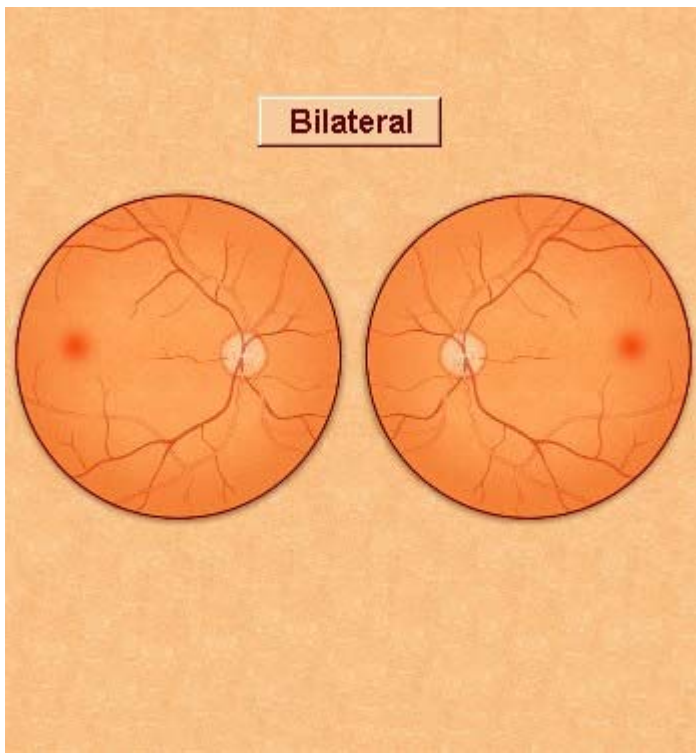
Social History: Patient denies alcohol use. Patient denies illegal drug use. Patient denies STD history. Patient denies tobacco use.

Family History: Patient/Guardian admits a family history of cataract associated with mother, maternal grandmother.

Review of Systems: Eyes: (-) blurred vision, (-) dry eyes, **Musculoskeletal:** (-) joint pain.

Physical Exam:

Constitutional: Patient is a pleasant, 48 year old male in no apparent distress who looks his given age, is well-developed and nourished with good attention to hygiene and body habitus.



Eye Exam:

Visual acuity - uncorrected: OD: 20/100 OS: 20/200 OU: 20/100

Refraction:

Lenses - final:

OD: +0.50 -1.50 X 125 Prism 2.00 Base Up Far VA 20/25

OS: +6.00 -3.50 X 125 Prism 2.00 Base Down

Add: OD: +1.00 OS: +1.00

Pupils: Pupil exam reveals round and equally reactive to light and accommodation.

Motility: Ocular motility exam reveals gross orthotropia with full ductions and versions bilaterally.

Visual Fields: Confrontation VF exam reveals full to finger confrontation OU.

IOP Method: applanation tonometry OD: 10 mmHg Medications: Alphagan; 0.2% Condition: improving. IOP

Date and Time: 8/1/2007 5:32:00 AM.

Keratometry:

OD: K1 35.875 K2 35.875

OS: K1 35.875 K2 41.875

Lids/Orbit:

Lids and lashes in normal position without infection bilaterally.

Conjunctiva white and quiet bilaterally.

Slit Lamp:

Corneal epithelium is intact with normal tear film and without stain. Stroma is clear and avascular. Corneal endothelium is smooth and of normal appearance.

Anterior Chambers: Anterior chambers are deep without cell or flare OU.

Lens: Lens are transparent and in normal position OU.

Posterior Segment:

Posterior segment was dilated bilateral.

Optic discs with normal color, contour and cupping bilaterally.

Retinas: Retinas are flat with normal vasculature out to the far periphery with no peripheral holes, breaks or tears observed.

Macula: Macula with normal reflex and color OU.

Test Results: No tests to report at this time.

Impression:

Eye and vision exam normal.

Plan:

Follow-up: **Scheduling:** Return to the office in 12 month(s).

Patient Instructions:

Patient was given verbal and written instructions regarding eye care following pupil dilation.

_____ Full Optom,

Optometry Clinic
1025 Ashworth Road, Suite 222
West Des Moines, IA 50265

PRESCRIBER: An. Optometrist, MD
TELEPHONE: (515)327-8850
DEA: 123456789

PATIENT:
John Doe
123 Main Street
West Des Moines, IA 50265
515-123-7890
DOB: 8/23/1958

DATE: 8/1/2007

OD:+0.50 -1.50 X 125 Prism: 2.00 BASE Up

OS:+6.00 -3.50 X 125 Prism: 2.00 BASE Down

Add: OD +1.00 OS +1.00

SIGNATURE OF PRESCRIBER

Billing Statement - Wednesday, August 01, 2007

Provider: Full Optom
Patient: John F Doe, Chart 13155
123 Main Street
West Des Moines, IA 50265

Diagnoses

1. V72.0 Examination Of Eyes And Vision

Treatments

1. 92004 Ophthalmological Services: Medical Examination And Evaluation With Initiation Of Diagnostic And Treatment Program; Comprehensive, New Patient, One Or More Visits
Related Diagnoses: V72.0

Modifiers:

Units:



Referring Physician: Full General, MD

Date Last Seen:

8/1/2007

Full General, MD
1501 South Park Rd
West Des Moines, IA 50266

Dear Dr. General:

John Doe was seen in my office in consultation as requested by you for evaluation and care. The following is a summary of my findings and recommendations:

Impression:

Eye and vision exam normal.

Plan:

Orders:

Follow-up: **Scheduling:** Return to the office in 12 month(s).

Patient Instructions:

Patient was given verbal and written instructions regarding eye care following pupil dilation.

If I may be of any further assistance in the care of your patient, please let me know. Thank you for providing me the opportunity to participate in the care of your patients.

Sincerely,

Full Optom

Patient Instructions for John Doe on 8/1/2007

YOUR EYES HAVE BEEN DILATED

Dilation drops temporarily increase the size of your pupils. This lets us accurately investigate the health of your eyes and other important general health aspects. Dilation of your eyes is a temporary inconvenience; however, benefits far outweigh the inconvenience.

The effects of eye dilation drops will gradually decrease. It typically takes TWO to SIX HOURS for the effects to wear off. During this time, reading may be more difficult and sensitivity to light may increase. For a short time, wearing sunglasses may help. Notify us if you feel your long distance vision is blurred excessively before attempting to drive. Your patience during this very important procedure is appreciated!

CALL MY OFFICE IMMEDIATELY IF YOU EXPERIENCE EXCESSIVE PAIN, DISCOMFORT OR NAUSEA
AT 515-327-8850

REMEMBER TO HAVE REGULAR MEDICAL EYE EXAMINATIONS.

Eye disease can occur at any age. Since most blindness is preventable if diagnosed and treated early, it is extremely important to have regular eye examinations. Keep in mind that many eye diseases are asymptomatic until after the damage to the eye has already occurred so early detection is the key. Use this as a reminder to plan for regular eye examinations to maintain sight throughout a lifetime.

Full Optom